

## Survival to amputation in pre-antibiotic era: a case study from a Longobard necropolis (6<sup>th</sup>-8<sup>th</sup> centuries AD)

Ileana Micarelli<sup>1,2</sup>, Robert Paine<sup>2</sup>, Caterina Giostra<sup>3</sup>, Mary Anne Tafuri<sup>2</sup>, Antonio Profico<sup>2</sup>, Marco Boggioni<sup>4</sup>, Fabio Di Vincenzo<sup>2</sup>, Danilo Massani<sup>5</sup>, Andrea Papini<sup>4</sup> & Giorgio Manzi<sup>2</sup>

1) Sapienza Università di Roma, Dipartimento di Scienze dell'Antichità, P.le Aldo Moro 5, 00185 Roma, Italy

2) Sapienza Università di Roma, Dipartimento di Biologia Ambientale, P.le Aldo Moro 5, 00185 Roma, Italy  
e-mail: maryanne.tafari@uniroma1.it

3) Università Cattolica del Sacro Cuore, Dipartimento di Storia, archeologia e storia dell'arte, Lrg. Agostino Gemelli, 1 - 20123 Milano, Italy

4) Scuola di Paleoantropologia, Piazza Università 1, 06123 Perugia, Italy

5) Policlinico Umberto I, Sapienza Università di Roma, Diagnostica per immagini in emergenza e urgenza, DEA, P.le Aldo Moro 5, 00185 Roma, Italy

**Summary** – The Longobard necropolis of Povegliano Veronese dates from the 6<sup>th</sup> to the 8<sup>th</sup> centuries AD. Among the 164 tombs excavated, the skeleton of an older male shows a well-healed amputated right forearm. The orientation of the forearm fracture suggests an angled cut by a single blow. Reasons why a forearm might be amputated include combat, medical intervention, and judicial punishment. As with other amputation cases reported in literature, this one exhibits both healing and osteoblastic response. We argue that the forelimb stump morphology suggests the use of a prosthesis. Moreover, dental modification of RP shows considerable wear and smoothing of the occlusal surface, which points to dental use in attaching the prosthesis to the limb. Other indications of how this individual adjusted to his amputated condition includes a slight change in the orientation of the right glenoid fossa surface, and thinning of right humeral cortical bone. This is a remarkable example in which an older male survived the loss of a forelimb in pre-antibiotic era. We link archaeological remains found in the tomb (buckle and knife) with the biological evidence to show how a combined bioarchaeological approach can provide a clearer interpretation of the life history of an individual.

**Keywords** – Medieval, Italy, Amputated forearm, Prosthesis, Humeral cross-section.

### Introduction

Evidence of trauma in past skeletal samples has been widely discussed in terms of violence and conflict (Paine *et al.*, 2007; Walker, 2001), with its related influence on mortality (Larsen, 1997). Interventions and related medical treatments, applied to individuals found in historical and prehistorical burials, for example trepanations as discussed by Arnott *et al.* (2003), or other

surgical interventions as mentioned by Brothwell & Moller-Christensen (1963), have been documented. Well-healed limb amputations are a specific skeletal indicator of traumatic intervention to the human body, whether done as medical intervention or intended violence. As a rule, amputations seen among archaeological burials are uncommonly observed by bioarchaeologists and therefore are not well discussed in the literature. The exceptions to this include publications specific

to the forearm (Brothwell *et al.*, 1963; Mays, 1996), to the ankle joint (Verano *et al.*, 2000; Więckowski, 2016; Weaver *et al.*, 2000), a bilateral foot loss (Stuckert *et al.*, 2011) and a peri-mortem case of foot amputation (Fernandes *et al.*, 2017). Critical discussions specific to individual survival with an amputated limb are nearly non-existent in the anthropological literature (Dettwyler, 1991).

In this paper, we discuss the biological and cultural evidence associated with a forelimb amputation. The burial examined comes from the Longobard necropolis of Povegliano Veronese (Veneto, Northern Italy). There are a number of biological features to suggest that an amputation had taken place: these include a change in the right glenoid fossa surface morphology, loss of the right radius and ulna diaphysis (along with the right hand), and extreme occlusal surface wear of the upper right second incisor. There is also healing of the fracture site with osteoblastic response associated with biomechanical loading. Along with the biological evidence, there is considerable cultural evidence from the grave goods found in the burial that also points towards an amputated condition of the forearm.

Our purpose with this case study is to provide a detailed description of the osteological and dental changes that occurred as a result of this individual's adjustment to an amputated forearm; we also link the biological evidence for this with cultural artefacts found in the burial.

## Material and Methods

### *Archaeological background of the cemetery*

The Longobard necropolis of Povegliano Veronese, discovered in 1985, is located in the Veneto region of Northern Italy. The Longobard community associated with this necropolis was founded shortly after the Longobard invasion of Italy in 568 AD (Giostra, 2014). The necropolis is situated 15 km southwest from the city of Verona in the locality of "Madonna dell'Uva Secca" (45°21'17.4"N 10°54'12.8"E), on the fringe of the "Via Postumia", one of the main ancient Roman roads of Northern Italy (Fig.1).

The necropolis was excavated during two field seasons (1985-86 and 1992-93). Longobard archaeologists often use the artefacts found at the site to estimate the age of the site. Specifically, grave goods like ornaments, buckles and weapons are used for this purpose (Paroli, 2007).

For this necropolis archaeologists used two brooches found in a female burial to develop the chronological estimation of the site. As a result, Giostra (2014) determined that the site is dated post 568 AD. The archaeologist have reported that the cemetery was in use for a century and a half (Bruno *et al.*, 2012).

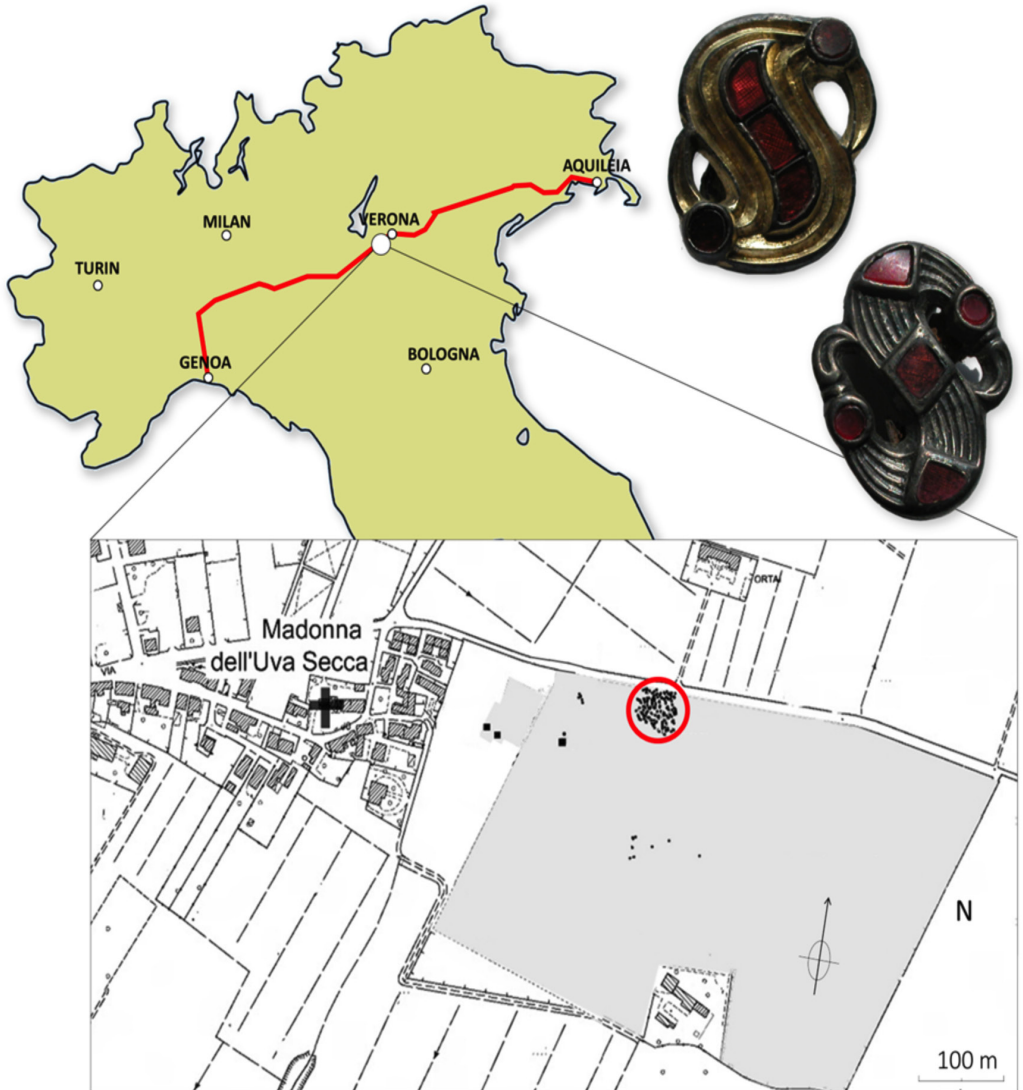
Along with human burials, a headless horse with two greyhounds were also found in a large pit at this necropolis. This is a common form of animal offering typically found in Longobard necropolises (Paroli, 2007).

As for the human burial discussed here, the majority of tombs contained single individuals. Yet, 14 of the 164 Longobard tombs excavated contained multiple bodies (Micarelli, 2015). From the 164 tombs, we observed 222 individuals. As the skeletal sample was examined, it became apparent that one of the individuals exhibited a well-healed amputated forearm; the palaeopathological assessment of this individual is the focus of this study.

### *Demographics*

Many of the human skeletal remains from the necropolis of Povegliano Veronese are reasonably well preserved. The demographics for these burials were estimated using standard osteological age at death methods (Brooks *et al.*, 1990; Lovejoy *et al.*, 1985) and sex identification methods (Acsádi *et al.*, 1970; Buikstra *et al.*, 1994; Phenice, 1969). Fifty-five of the burials are of sub-adults ranging from 0-20 years of age. The cemetery contained 169 adults (aged 21-50+ years), 45 males, 44 females and 80 indeterminate adult burials. The high number of indeterminate adult burials is caused by the lack of reliable features used to identify sex.

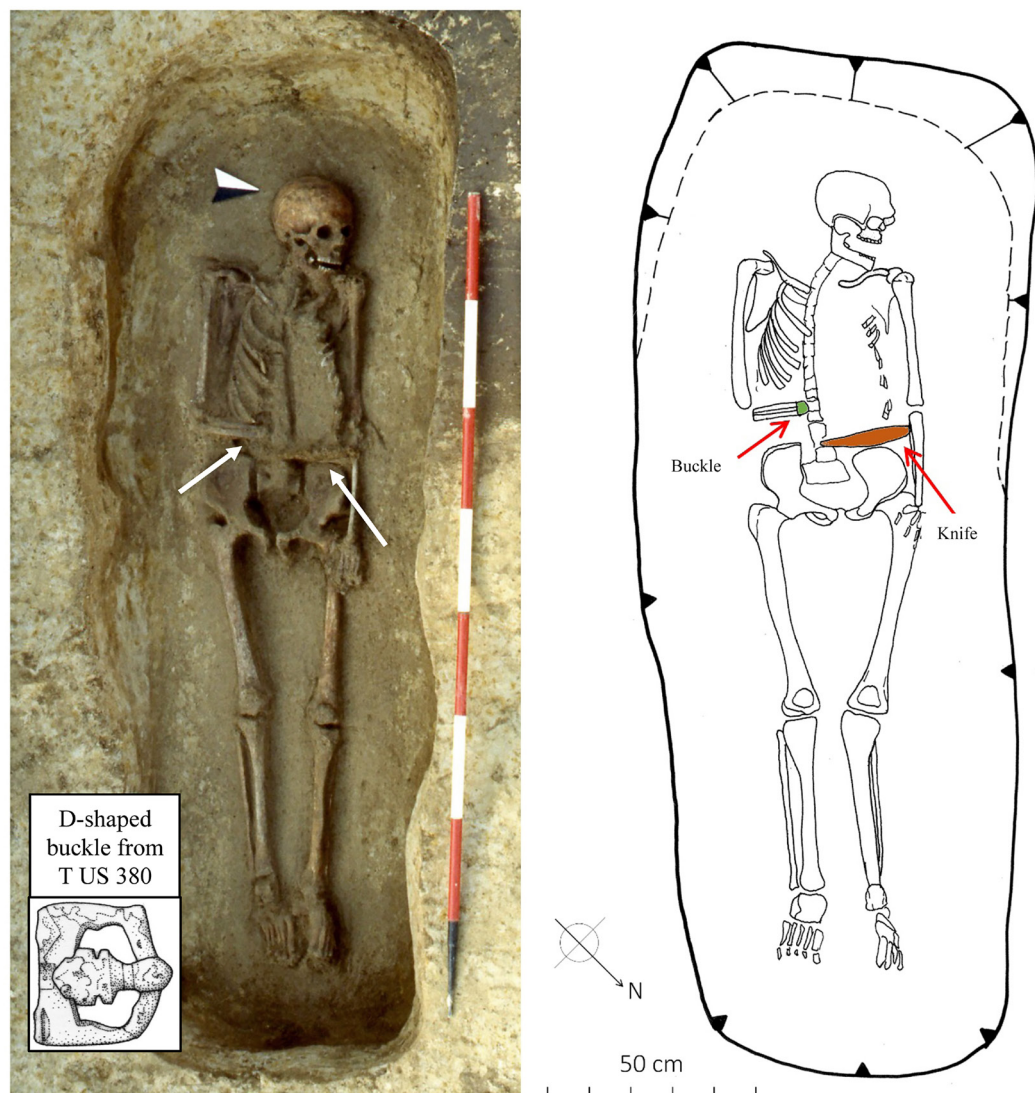
The male skeleton with the well-healed amputated right forearm comes from tomb T US 380 (Figs. 2 and 3).



**Fig. 1 - The location of the Longobard cemetery, near Verona, north-eastern Italy. The S-shaped brooches from the site provided a time depth for the burials (late 6th century AD). The red line represents the ancient Roman way known as Via Postumia. The light grey zone in the excavation map represents the burial area, and the circle in red delimits the location of T US 380 (after Giostra, 2014). The colour version of this figure is available at the JASs website.**

The sex and age at death of this individual was based on the observation of morphological traits of both the skull and the pelvis (Acsádi *et al.*, 1970). Age estimation for the individual was carried out

by examining the occlusal wear of all available teeth (Lovejoy, 1985), the remodelling of the pubic symphysis surface following Brooks & Suchey (1990) and changes in the auricular surface of the ilium



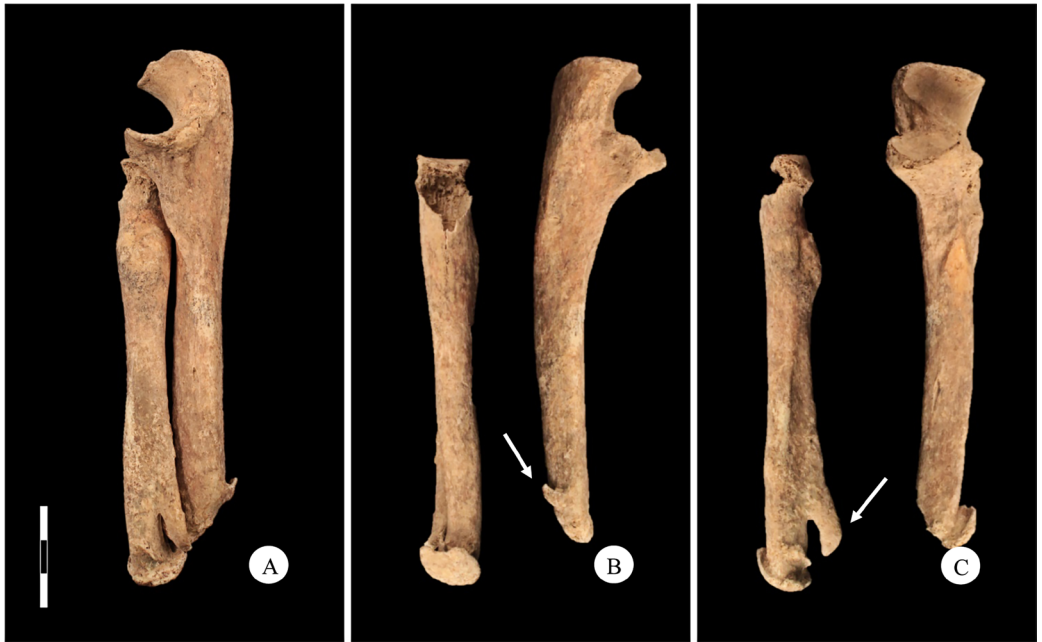**Fig. 2 - Photo and drawing of T US 380. Notice the orientation of the right arm, the position of the D-shaped buckle and the location of the knife. Unlike most burials, the right arm of the individual was bent over the pelvis in correspondence of both buckle and knife (burial photo and drawing are kindly provided by Dr. Gianni De Zuccato and Dr. Brunella Bruno of the Soprintendenza per i Beni Archeologici del Veneto in Verona). The colour version of this figure is available at the JASs website.**

(Lovejoy *et al.*, 1985). The burial found in tomb US 380 is that of a male, with a mean age of 47 years and a range in age of 40-50 years. The specific assessment criteria for the sex and age determinations are provide in Table 1.

#### *Archaeological context of burial T US 380*

The necropolis of Povegliano Veronese is divided into several sections. The largest section of the necropolis with burials is found in the northern part of the necropolis. This is where T





**Fig. 3 - Right forearm healed fracture of T US 380; anterior view (A) with detail of the osteophytes and bone spurs on the ulna (B) and on the radius (C). The colour version of this figure is available at the JASS website.**

US 380 was found. Tomb US 380 is a single pit burial, located in the Northern region of the site (Hudson, 1996). This section of the necropolis also features the deposition of a headless horse and two dogs, which has cultural significance for the Longobards (Paroli, 2007). Additionally, culture-defining artifactual evidence includes the presence of S-shaped bronze brooches and D-shaped bronze buckles (Fig. 1) which are a clear chronological signal for early Longobard occupation (Giostra, 2014). The construction of *Tottenbrett tombs* (Rotili, 2010), is also evidence for the first generation of Longobards in Italy. The *Tottenbrett* burial structure is defined by a tomb cavity surrounded by four post-holes that held the tomb's wooden roof (Rotili, 2010).

The T US 380 burial pit was originally dug in clay-based soil without a coffin. The body was placed in the pit with the head pointing west-to-southwest. The grave-goods found in this tomb (Fig. 2) consist of a bronze D-shaped buckle and an iron knife (Hudson, 1996), the latter was found

in association with non-human organic material (probably leather). All of this material was found close to the end of right forearm. Each of these items was found in the grave at the mid-section of the body, by the pelvis. There are several lines of evidence to suggest that the individual buried in tomb US 380 is not originally from Povegliano. They include grave goods that date the burial to the last thirty years of the 6<sup>th</sup> century (Giostra, 2014), a time of migration from Eastern Europe to Italy. Strontium samples taken from dental enamel from this individual reveal that they do not match strontium levels normally found in Povegliano soil (G. Francisci, pers. comm.).

#### *Methods for the observation of skeletal traits linked to the amputation*

A gross pathological assessment of the epiphyses linked to the amputation (Fig. 3) of both the right ulna and radius were observed (Figs. 4A and 4B). All osteological measurements were taken with a sliding caliper.

**Tab. 1 - Sex and age demographics of T US 380 based on the observation of the morphological traits of the skull and the pelvic bone (for sex estimation) and dental wear, ectocranial sutures and morphology of auricular surface and pubic symphysis (for age estimation). Mean estimated age is calculated for relative ranges.**

METHODS	SCORE	SEX, AGE MEAN AND RANGE
<b>SEX METHODS</b>		
Acsádi & Nemeskéri A (1970) – cranium	- 0.39	F
Acsádi & Nemeskéri B (1970) – bony pelvis	+ 1.2	M
Phenice C (1969)	No ventral arc, Narrow pubis, Narrow subpubic angle	M
		Estimation sex: M
<b>AGE METHODS</b>		
Lovejoy (1985): dental wear	Maxillary: Phase H Mandibular: Phase G	41.3
Meindl & Lovejoy (1985): suture	Cranial vault: 49.5 Lateral-anterior portion: 49.6	49.5
Brooks & Suchey (1980)	Phase 5 (28 – 78)	45.6
Lovejoy <i>et al.</i> (1985)	Phase 6 (45 – 49)	47
		Estimated age range: 40-50

<sup>A</sup> Acsádi & Nemeskéri (1970) – cranium: 18 morphological features are assessed;

<sup>B</sup> Acsádi & Nemeskéri (1970) – pelvis: 11 morphological features are assessed;

<sup>C</sup> Phenice (1969): 3 pelvic features are assessed.

A 3D model of the amputation location for both bones was obtained through CT-scan. The left and right glenoid fossa surfaces were examined (Fig. 5).

Dental modification (Hillson, 2005) of the right upper second incisor (RI<sup>2</sup>) was observed. The tooth showed considerable wear and smoothing of the occlusal/anterior surfaces compared to the other maxillary teeth (Fig. 6).

Specifically, this dental defect was examined with a Vistascan X-ray scanner. Relative enamel loss of this tooth was measured from the buccal view with standardized sliding callipers and then this loss was compared to the LI<sup>2</sup> enamel height. We also looked at the morphology of teeth surrounding both incisors via X-ray scanner (Figs. 6B and 6C).

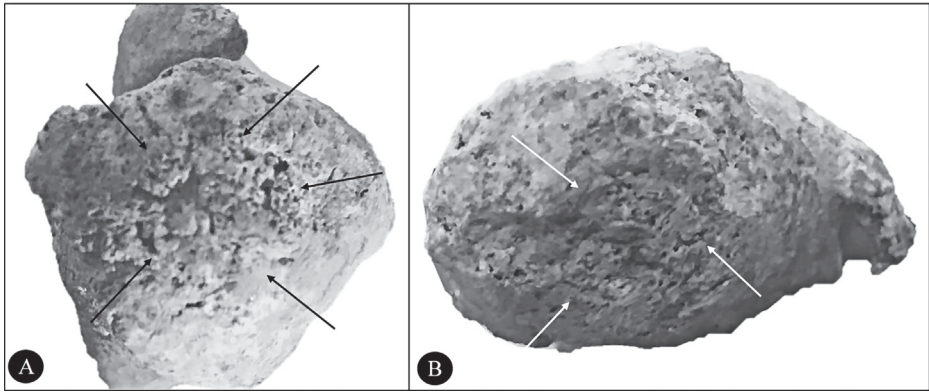
#### *Digital data acquisition*

The entire skeleton of T US 380 was scanned with a Siemens SOMATOM Sensation 16 CT-scanner. The scanning was done at the Policlinico Umberto 1 at Sapienza University in Rome, Italy. Images of both the humeri were taken at 0.75mm increments (i.e., interslice distance). Scanned data were exported as DICOM files, with a matrix of 512X512 pixels and a pixel size of 0.88 mm.

For the purpose of this report, the humeral bones were divided into 21 segments starting from the distal to the proximal epiphysis using Amira (ver. 5.4.5). These are the specific cross-sectional segments assessed for the geometric data presented in this paper (Fig. 7). The Arothron package (Profico *et al.*, 2015) was used to assess the cross-sectional geometry of each humerus in the R environment.

The 21 CT-scanned images of the left and right humeral diaphyses were measured for diaphysis perimeter (P), total cross-sectional area (TA), cortical thickness (CT) and cortical area (CA) (Fig. 7). Percent cortical area was determined by  $CA/TA * 100$ . Cortical thickness was measured at the four anatomical quadrants (anterior, posterior, medial and lateral). CT was then defined as the averaged cortical thickness for each CT-section  $(A+M+P+L/4)$ . Cortical area is measured as total cross-section area minus medullary cavity area.

A two-tailed t-test was applied to the cortical thickness, cortical area, percent cortical area



**Fig. 4 - The distal caps for both the radius (4A) and ulna (4B). Notice the raised remodel bone central to the end caps.**

and perimeter values for both the left and right humeral diaphyses. The metric acquisition and the statistical analysis were performed with R statistical software (R Core Team, 2000).

## Results

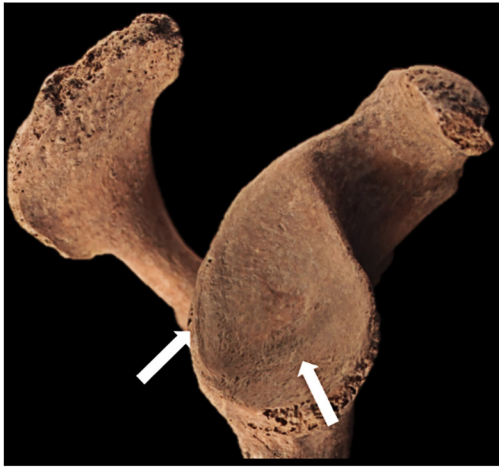### *Forearm Lesions*

The male burial, T US 380 exhibits several skeletal defects that reflect changes due to the amputated forearm. These skeletal lesions and modifications include the well-healed callous surfaces at the fracture location for both the right ulna and radius (Fig. 3). The CT-scan of the forearm fracture site suggests an angled cut to the ulna and radius caused the defect. The cut is at a 31-degree angle, running left to right, lateral to medial in direction towards the centre of the body. Even though the ulna is longer than the radius, the lateral side of the forearm is longer than the medial side. The fracture edge is located on the proximal third of the long bone diaphyses (radius length 126 mm; ulna length 142 mm). At the amputated edge of the radius, the antero-posterior diameter (with lipping) measures 20 mm, while for the ulna the diameter is 10 mm. The amputated stumps also show surface remodelling on both bones (Figs. 4A and 4B). Bone texture of the remodelled surface is granulated and porous at the mid-point of the callous. The

distal end of radius has a medio-lateral diameter of 15 mm, while that of the ulna is 14 mm. Total circumference of the amputated edge is 52 mm for the radius and 41 mm for the ulna (including lipping). Along with the healed surface there are large osteophytes, primarily on the lateral side of the radius and the medial side of the ulna (Fig. 3A). There is also a large (36 mm) ossification of interosseous tissue extending from the radial diaphysis towards the ulnar diaphysis (Fig. 3B). A much smaller bone spur on the posterior/medial surface of the ulna diaphysis is located 7 mm from the fracture line (Fig. 3C). It is possible that if this individual had lived longer, the bones eventually would have fused at these surfaces in response to biomechanical stimuli.

### *Humeral metrics*

The analysis of humeral lateralization using the percent of directional asymmetry (%DA) (Auerbach *et al.*, 2006) equation performed on T US 380 does not show any difference between the right and the left humerus at the midshaft (1.02%), although some difference is evident at 35% of the length from the distal epiphyses (0.73%). The results are consistent with corresponding values observed in other male individuals at Povegliano Veronese. Specifically, only two and one individual respectively show significant lateralization ( $\leq 3\%$ ) at midshaft and at 35% of the length from the distal epiphyses.



**Fig. 5 - T US 380, a modified right glenoid fossa surface, the arrows point to a c-shaped ridge. The colour version of this figure is available at the JASs website.**

The results of the digital analysis indicate that the humeri exhibit considerable differences in cortical bone thickness and cortical cross-sectional area (Tab. 2, Fig. 7).

The 21 humeral cross-sections were measured for each of the variables (i.e., humeral cortical area, total cross-sectional area, cortical thickness, and shaft perimeter). The data are distributed normally. The two-tailed T-test shows that the total (A+P+L+M) cortical thickness of the two humeri from T US 380 is significantly different (mean right = 4.77 mm, mean left = 5.43 mm,  $p=0.04$ ), as is cortical bone area ( $p<0.01$ ). The difference in values for the humeral % cortical area and external diaphysis perimeter are not statistically significant (Tab. 3).

#### *Glenoid fossa*

An observation of the right glenoid fossa showed a c-shaped ridge running from the dorsal side of the glenoid fossa edge into the mid-area of the fossa surface; its presence suggests a change in the orientation of the upper arm bone (Fig. 5). This c-shaped ridge measures approximately 17.7 mm along the dorsal side of the fossa and 20.8 mm from the glenoid edge. In total, the ridge is approximately 38.5 mm in length.

This specific glenoid defect was not observed in any other individual from this skeletal sample ( $n=10$ ).

#### *Dental defects*

The crown height of the right upper second incisor (RI<sup>2</sup>), measured from the CEJ, reveals considerable occlusal surface wear and enamel loss compared to the surrounding teeth. Specifically, the length from the buccal view of RI<sup>2</sup> (Fig. 6A) is only 2.7 mm, while the length of the buccal view of LI<sup>2</sup> is 4.7 mm (twice the length). The anterior portion of the RI<sup>2</sup> (Figs. 6A and 6B) shows extreme smoothing of its surface, an indication of tooth use for other than mastication. Additionally, a periapical lesion (5.4 mm in diameter) was found at the proximal end of the RI<sup>2</sup> root (Fig. 6C).

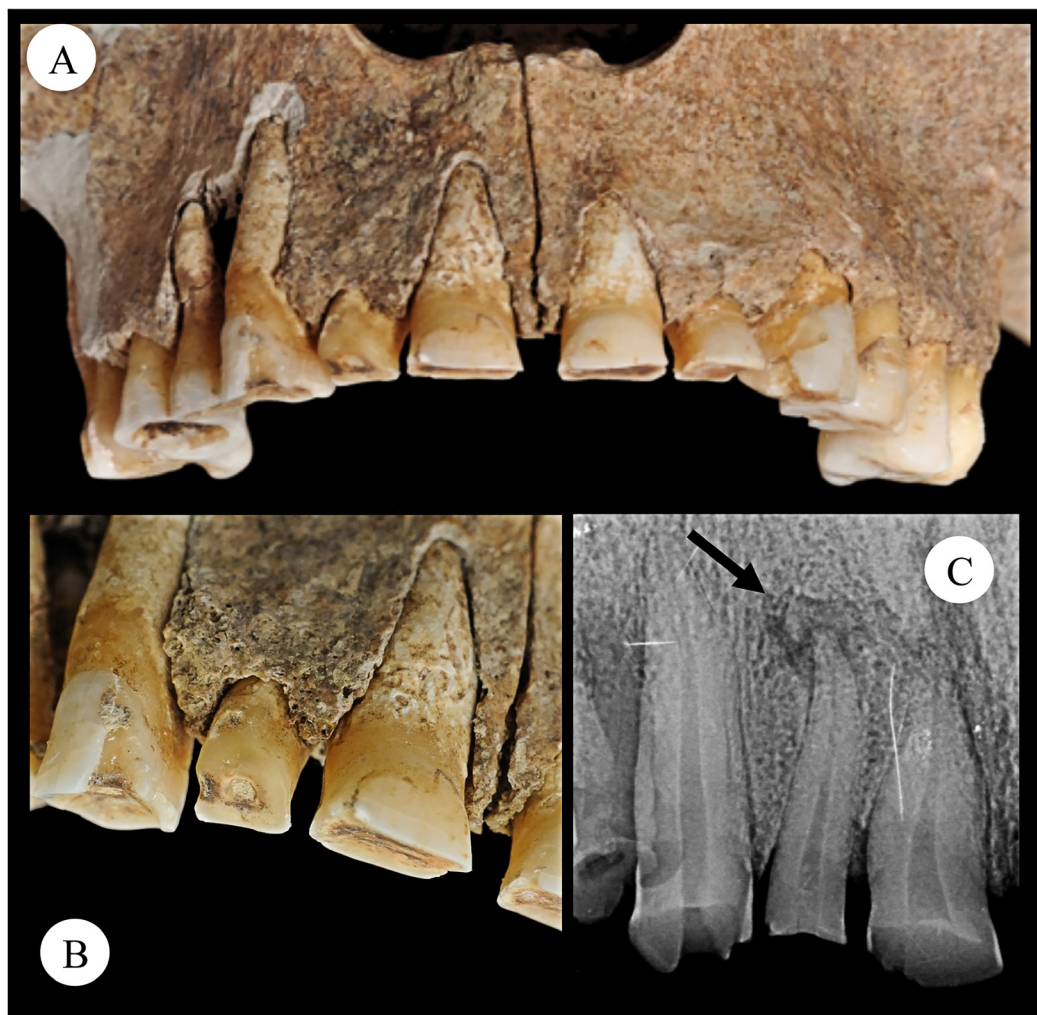
T US 380 presents a considerable amount of dental wear in all of his teeth. The right side of the dental arcade shows more evidence of wear than the left side. Root exposure is visible on all of the maxillary and mandibular teeth, and this is a clear indication of ante-mortem bone loss along the alveolar surface. This is observed specifically on the RM<sup>2</sup>, RM<sup>3</sup>, LM<sup>2</sup>, LM<sup>3</sup>, RM<sub>1</sub>, RM<sub>2</sub>, LM<sub>1</sub> and LM<sub>2</sub>.

Beside the skeletal lesions specific to the amputation we found evidence of osteoarthritis of the spine, specifically in the form of slight lipping of the thoracic vertebral bodies, and on the superior and inferior facets.

## **Discussion**

There are a number of conditions that can lead to limb loss, including: healed necrosis (Cieřlik *et al.*, 2017), congenital defects (Tilley *et al.*, 2011), peri-mortem loss/amputation (Fernández *et al.*, 2015), post-mortem loss/amputation (Fernandes *et al.*, 2017), and ante-mortem loss/amputation (Stuckert *et al.*, 2011). We excluded the first four conditions because none of the features observed in burial T US 380 matched the features of these circumstances (Tab. 4).

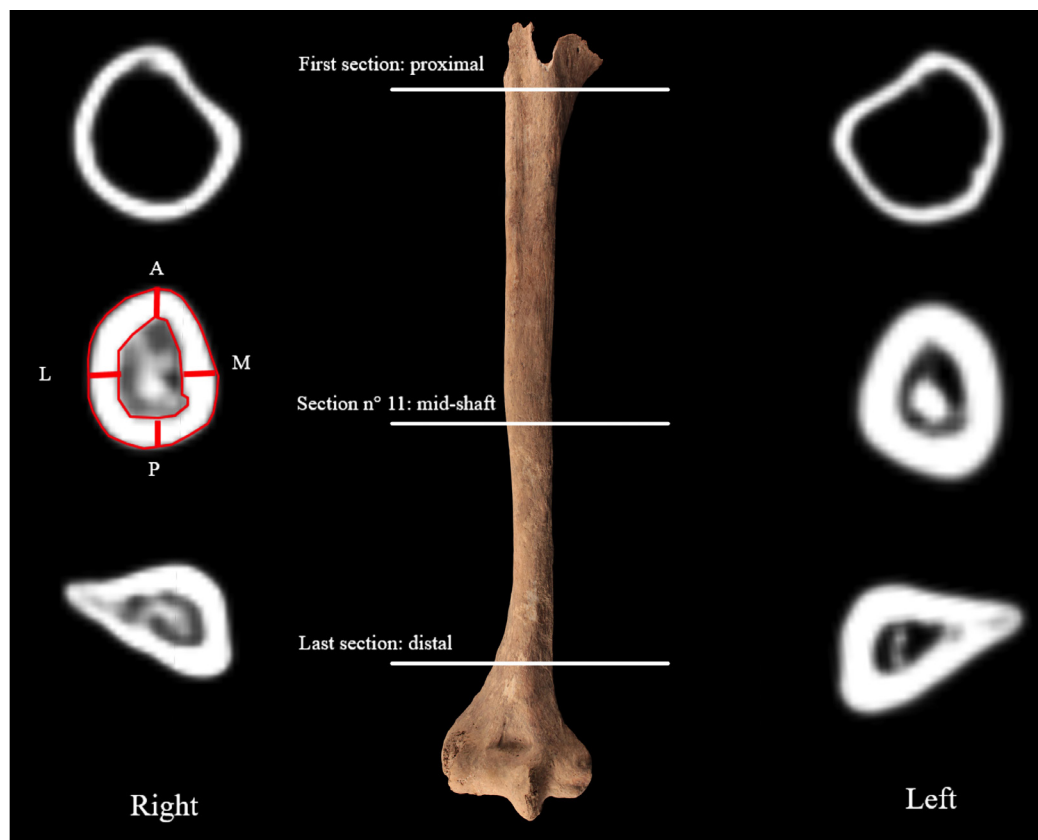




**Fig. 6 - Buccal view of surface wear of the RI2 (A and B); type and orientation of wear is a clear indication of the extra-masticatory use of the tooth, which shows a crown significantly reduced (if not obliterated) in comparison to the left second incisor. (C) X-ray of the right upper second incisor tooth, notice the periapical lesion located at the proximal end of the root, T US 380. The lighter coloured bone around the margins of the exposed tooth roots RI2 is the result of post-mortem damage. The colour version of this figure is available at the JASs website.**

T US 380 provides us with the rare opportunity to combine cultural evidence with biological data to explain the amputation in this individual. First, we compare the amputated forelimb morphology of T US 380 with that of other examples cited in the literature (Tab. 5). There is a similar trend in morphology among the three cases. The

presence of bone spurs highlights this trend. Each of the cases found from the literature presents a well-healed callous at the fracture location. The difference among them is the proportion of the diaphysis lost to amputation. T US 380 shows the greatest diaphyseal loss, with the cut being proximal to the mid-shaft of the radius and ulna.



**Fig. 7 - CT Scans for both left and right humeral cross-sections, proximal (21), mid-shaft (11), and distal (1), T US 380. All three sections show considerable cortical bone loss (mean loss 8.88%) as a result of reduced mobility of the limb; this is frequently observed in individuals using a prosthesis. The colour version of this figure is available at the JASs website.**

Secondly, the pattern of skeletal defects and dental modification in T US 380 tells us several things about the life history of this individual. The amputation occurred as blunt force trauma to the forearm. There are several reasons why a forearm from this cultural period might be amputated. One possibility is that the limb was amputated for medical reasons; perhaps the forelimb was broken due to an accidental fall or some other means, resulting in an unhealable fracture. The formation of bone necrosis might have led to a surgical intervention to remove the dead tissue from the healthy part of the limb (Nemes, 2002).

Still, given the warrior-specific culture of the Longobard people, a loss due to fighting is

also possible. Bedini and Bertoldi (2004) found cranial trauma evidence to suggest that many of Longobard males were involved in warfare activities and had received traumatic injuries as a result of fighting. Longobard shields found at the burial site of Collegno exhibit damage patterns similar to the trauma found on the skulls of Longobard warriors from this period. All of the archaeological evidence supports a scenario specific to war injury. A third consideration for why the limb was amputated would be loss due to judicial punishment. This form of punishment did occasionally occur among the Longobard people (Metzler, 2013). Moreover, all of these events match a scenario by which the forelimb

**Tab. 2 - Humeral metrics for burial T US 380 taken at 21 points along diaphyseal regions. For each region percentage cortical area and percentage bone loss are provided.**

LONG BONE REGION	CORTICAL THICKNESS (MM)								% CORTICAL AREA			EXTERNAL PERIMETER (MM)	
	RIGHT				LEFT				RIGHT	LEFT	% BONE LOSS (RIGHT VS. LEFT)	RIGHT	LEFT
	A	P	M	L	A	P	M	L					
Proximal	1.12	2.77	2.88	2.98	3.75	3.31	2.84	3.58	43.31	47.33	4.02	76.27	79.24
Mid-shaft	4.83	5	5.36	5	5.23	6.35	5.39	6.74	71.34	81.32	9.98	65.29	64.63
Distal	5.31	4.47	4.86	5.43	6.18	8.11	5.36	5.85	82.42	93.54	11.12	68.23	72.02
Mean*	3.75	4.08	4.37	4.47	5.05	5.92	4.53	5.39	65.69	74.06	8.37	69.93	71.96

Humeral metrics reported for 3 cross-sections in correspondence to the distal region (1), mid-shaft (11) and proximal region (21). The measurements of the cortical bone thickness at different orientations (A = anterior; P = posterior; M = medial; L = lateral). \*The mean is taken from all 21 sections.

was purposely amputated. It is possible that the individual cutting the arm used the right hand as they stood in front of the amputee. This would be possible if the individual was standing while fighting, or laying on a table during surgery, or sitting on a stool with the arm resting on a table during punishment.

Mays (1996) describes a case of amputation during Medieval times that may have been the result of judicial punishment. A second look at the Brothwell & Moller-Christensen case (1963) with the two inner facing angles to the fractures suggests that the fractured forearm bones might actually be half of a survived butterfly fracture of the forearm. Hence the amputation may have been caused by blunt force trauma and not a bladed weapon, where the surgeons would have followed the line of the fracture.

The Longobard male survived the loss of the forearm even though antibiotics were not readily available. This highlights a community level effort to provide an ideal setting for healing to take place. This suggests a clean environment and intensive care during the early stages of healing, with the ability to prevent death from blood loss. Specific herbal balms were available to the

Longobard people for this purpose (Fornasaro, 2008). This fact strongly supports the idea that the limb loss was due to combat or surgical intention. It seems less likely that a criminal would have been given such successful medical treatment.

Third, the round shaped callous on both bones, along with the osteophytes, suggest that there may have been a biomechanical force placed on the stump. The pressure of the bone against a prosthesis could have produced the biomechanical force required to create the callous and the bony bridge that became the structurally stable support between the two bones. It could also account for the surface remodelling of the epiphyses of both bones. Earlier cases of prosthesis use are found in Egypt (950-710 BD, Finch, 2011), as well as in China (3<sup>rd</sup>-2<sup>nd</sup> century BC, Li *et al.*, 2013) and Medieval Austria (Binder *et al.*, 2016).

Additional biocultural evidence supporting the prosthesis hypothesis includes dental modification. Along with the extreme enamel loss, we found a granulomatous bone lesion (periapical lesion) located at the proximal end of the root for RI<sup>2</sup> (Fig. 6C). This periapical lesion is

**Tab. 3 - T-test results measuring differences in area and perimeter of the cortical bone between left and right humerus of T US 380.**

VARIABLE	P-VALUE	STANDARD ERROR OF THE MEANS
Cortical area (%)	0.09	3.94
Cortical area (mm)	<b>&lt;0.01</b>	5.52
Cortical thickness	<b>0.04</b>	5.52
Perimeter	0.68	1.35

The cortical thickness is represented by  $(A+P+M+L)/4$ ;  
p-values in bold are statistically significant.

most likely associated with the extreme occlusal wear of the tooth, which opened the pulp cavity causing a bacterial infection and the resorption of the maxillary bone. Furthermore, there is the polished anterior surface of RI<sup>2</sup>, which we suggest occurred by non-masticatory processes as he tightened the prosthesis in place. Furthermore, we suggest that the reorientation of the shoulder joint, as evidenced by the c-shaped ridge seen on the glenoid surface, indicates that tightening the prosthesis with his teeth placed the shoulder joint in an abnormally extended position and that this happened frequently, thereby creating the bony ridge seen on the right glenoid surface (Fig. 5). Therefore, we suggest that this additional line of evidence supports the assertion that this individual did use a prosthesis.

From the archaeological evidence provided by Hudson (1996), we suggest that a prosthesis might have taken the form of a cap with a modified bladed weapon attached to it. At the end of the amputated site of the forearm, the archaeologists found a D-shaped buckle (Fig. 2) with decomposed organic material (most likely leather) surrounding it. Given the position of this material in the grave, it is possible that leather bindings that held the cap with the knife degraded allowing the buckle and weapon to fall slightly from their original position. A review of the original report by the excavators (Hudson, 1996) shows that all

male burials with knives had their arms located at the sides of the body. The exception to this was T US 380: his right arm is bent at the elbow pointing in the direction of the mid-section of the body, where the butt of the knife is located (Fig. 2).

CT-scans of the right humeral diaphysis show that this bone underwent cortical bone loss from the proximal to the distal end (Fig. 7), which often happens with the presence of a prosthesis (Minaire, 1989; Sievänen, 2010). It suggests that the right arm of T US 380 was not used for weight bearing or normal mechanical activities, certainly not used for carrying heavy objects.

A comparison of the percent of cortical bone area in the right proximal, mid-shaft and distal humeral cross-sections show a mean loss of 8.88% cortical bone relative to those of the left humerus (Tab. 2). These findings are not surprising given the well-healed nature of the radius and ulna. The well-healed condition of the amputated forearm tells us T US 380 lived for a considerable time after his forelimb loss. Hence, he lived long enough to lose cortical bone from the right humerus.

Thus, the Longobard man's life changed after the amputation. We may consider him as a disabled individual according to the definition of disability provided by the WHO (WHO, 2017 Health Topics: Disabilities, i.e., impairments, activity limitations, and participation restrictions), and the literature gives us an important perspective for interpreting his conditions. The paleopathology of other impaired/disabled individuals has also been documented (Belcastro *et al.*, 2001; Frayer *et al.*, 1987; Gracia *et al.*, 2009; Minozzi *et al.*, 2014; Solecki, 1975). The case from Sima de los Huesos dated to the Middle Pleistocene (Gracia *et al.*, 2009) testifies to a very early example of intentional care given to a disabled child affected by craniosynostosis and possibly cognitive impairment. In this case, community support guaranteed the survival of the child for 5 years. Minozzi & colleagues (2014) provide an example from the site of Castel Malnome, in which a male showed a temporomandibular joint ankylosis that led to the extraction of several teeth, which allowed him to be fed. Without this intervention, he would have starved.

**Tab. 4 - Differential diagnosis among pathological conditions that could lead to limb loss. A comparison with the literature favours the hypothesis of ante-mortem loss/amputation in consideration of the entity of bone remodelling and relevant callous bone.**

	LOCATION OF ORIGIN	BONE LOSS	CALLUS OSSEOUS	CLASSIC PATTERN OF LESIONS	BONE REMODELLING	LITERATURE
<b>HEALED NECROSIS</b>	Total skeletal system	Avulsion injuries	Possible	Bone loss	Yes, if the individual survives	i.e., (Cieřlik <i>et al.</i> , 2017)
<b>CONGENITAL DEFECT</b>	Limbs	No	No	Immobility, osteoporosis	No	i.e., (Tilley <i>et al.</i> , 2011)
<b>PERI-MORTEM LOSS/ AMPUTATION</b>	Total skeletal system	Amputated part of the body	No	Very slight remodelling	If the individual survives, after 15 days	i.e., (Fernández <i>et al.</i> , 2015)
<b>POST-MORTEM LOSS/ AMPUTATION</b>	Total skeletal system	Amputated part of the body	No	No remodelling	No	i.e., (Fernández <i>et al.</i> , 2015)
<b>ANTE-MORTEM LOSS/ AMPUTATION</b>	Total skeletal system	Amputated part of the body	Yes	Bone remodelling	Yes	i.e., (Stuckert <i>et al.</i> , 2011)
<b>T US 380</b>	Total skeletal system	2/3 of right forelimb	Yes	Bone remodelling	Yes	-

## Conclusion

This Longobard male shows a remarkable survival after a forelimb amputation during pre-antibiotic era. Not only did he adjust very well to his condition, he did so with the use of a culturally-derived device, along with considerable community support. Most likely, he had a prosthesis that was used to protect the stump. The archaeological evidence for this seems clear. The difference between T US 380 and all of the other male burials is emphasised by the arm position, the placement of the D-shaped buckle and the presence of organic material (bindings). This distinction is also indicated by the biological evidence. The RI<sup>2</sup> tooth wear, cortical bone loss of the right humerus, and slight change in right shoulder orientation suggest that a prosthesis was often fitted to the stump and that this repetitive activity had a profound effect on his dental and skeletal morphology.

The survival of this Longobard male testifies to community care, family compassion and a high value given to human life. A variety of interpretations and implications from skeletal evidence of injury such as this can inform us the motivations of others as they care for disabled individuals.

In the case of the Longobard male under study, the loss of the right limb might have not implied *basic* or *advanced* care (*sensu* Tilley *et al.*, 2011), but it must have had an impact on the community he belonged to. At a minimum, his lack of participation in community life could have necessitated some sort of compensatory actions by the rest of the group.

Skeletal evidence applied to the cultural ethnography of the past can aid in contextualizing the archaeological record. Typically, the linkage between human bone and human culture is restricted to archaeology or to living communities, but under the right conditions it can also be applied to burials from the archaeological record



**Tab. 5 - Comparison of amputated forearms among case studies from various cultural backgrounds and historical phases. Type of lesion and remodelling activity are observed. Specifically, the angle of the cut was related to position of the arm during amputation.**

SAMPLE	ULNA/ RADIUS FRACTURE LOCATION	ULNA BONE SPUR	RADIUS BONE SPUR	ANGLE OF THE CUT	REACTIVE REMODELLING OF THE CALLOUS	FOREARM ANKYLOSES	FOREARM ORIENTATION
Iron-Age Egypt IX Dynasty Sex unknown, adult <sup>A</sup>	mid-shaft	fused	fused	2 angles running to the mid-section of the forearm. 55 degrees right and 56 degrees left angle	unknown	yes	supination
Medieval England Male 30- 40 years <sup>B</sup>	distal	fused	fused	20 degrees right angled	unknown	yes	supination
T US 380 Longobard Male 40- 50 years	proximal	yes 7 mm	yes 36 mm	31 degrees left angled	yes	no	supination

<sup>A</sup> Brothwell & Moller-Christensen, 1963; <sup>B</sup> Mays, 1996.

that lack supporting historic documents. By using a bioarchaeological approach to examine a burial that combined specific osteological and dental observations with a well-documented set of archaeological indicators, we have shown that unique insights into human behaviour can be obtained. Thus, the present case study provides a unique scenario about the health history of a medieval male living in a cultural period that is not fully known to us. With careful observations from both anthropological sub-disciplines, the past can be further explored and new insights achieved. As with previous studies that highlighted amputation events in past communities, we now have a better understanding of medieval medical practices and their potential for positive outcomes.

## Acknowledgements

*Foremost, we deeply appreciate the work and help of the staff from Soprintendenza per i Beni Archeologici del Veneto in Verona, specifically the aid provided by*

*Dr. Gianni De Zuccato and Dr. Brunella Bruno, without whom this work would not be possible. We also would like to thank prof. G. F. Gualdi and dr. C. Di Biasi at the Unità Operativa of Policlinico Umberto I, Sapienza Università di Roma for providing access to a CT-scanner from the lab at Policlinico Umberto I, Sapienza University of Rome. We thank the three anonymous reviewers for helpful comments and suggestions. This research did not receive any specific grant from funding agencies in the public, commercial, or not-for-profit sectors.*

## References

- Acsádi G. & Nemeskéri J. 1970. *History of human life span and mortality*. Akadémiai Kiadó, Budapest.
- Auerbach B.M. & Ruff C.B. 2006. Limb bone bilateral asymmetry: variability and commonality among modern humans. *J. Hum. Evol.*, 50: 203-218.
- Bedini E. & Bertoldi F. 2004. Aspetto fisico, stile di vita e stato di salute del gruppo umano. In L. Pejrani Baricco (ed): *Presenze Longobarde in Italia*, Firenze.

- Belcastro M.G., Facchini F., Neri R. & Mariotti V. 2001. Skeletal markers of activity in the early Middle Ages necropolis of Vicenne-Campochiaro (Molise, Italy). *Journal of Paleopathology. Monographic publications*, 13: 9-20.
- Binder M., Eitler J., Deutschmann J., Ladstätter S., Glaser F. & Fiedler D. 2016. Prosthetics in antiquity—An early medieval wearer of a foot prosthesis (6<sup>th</sup> century AD) from Hemmaberg/Austria. *Int. J. Paleopathol.*, 12: 29-40.
- Brooks S. & Suchey J.M. 1990. Skeletal age determination based on the os pubis: a comparison of the Acsádi-Nemeskéri and Suchey-Brooks methods. *Hum. Evol.*, 5: 227-238.
- Brothwell D. & Moller-Christensen V. 1963. Medio-historical aspects of a very early case of mutilation. *Dan. Med. Bull.*, 10: 21-25.
- Bruno B. & Giostra C. 2012. Il territorio di Povegliano Veronese fra tarda antichità e alto medioevo: nuovi dati e prime riflessioni. *VI Congresso Nazionale di Archeologia Medievale (L'Aquila, 12-15 settembre 2012)*, pp. 216-222, Firenze.
- Buikstra J.E. & Ubelaker D.H. 1994. *Standards for data collection from human skeletal remains: proceedings of a seminar at the Field Museum of Natural History*. Arkansas Archaeological Survey Research Series, n. 40, Fayetteville.
- Cieřlik A.I., Dąbrowski P. & Przysiężna-Pizarska M.A. 2017. The face of conflict: Significant sharp force trauma to the mid-facial skeleton in an individual of probable 16<sup>th</sup>–17<sup>th</sup> century date excavated from Byczyna, Poland. *Int. J. Paleopathol.*, 17: 75-78.
- Dettwyler K.A. 1991. Can paleopathology provide evidence for “compassion”? *Am. J. Phys. Anthropol.*, 84: 375-384.
- Fernandes T., Liberato M., Marques C. & Cunha E. 2017. Three cases of feet and hand amputation from Medieval Estremoz, Portugal. *Int. J. Paleopathol.*, 18: 63-68.
- Fernández Á.P., Alemán I., Botella M.C. & Cunha E. 2015. Perimortem fractures in the osteological collection of Aljubarrota (Portugal). *J. Anthropol. Archaeol.*, 40: 82-88.
- Finch J. 2011. The ancient origins of prosthetic medicine. *Lancet*, 377: 548-549.
- Fornasaro F. 2008. *La medicina dei Longobardi*. Libreria Editrice Goriziana, Gorizia.
- Fraye D.W., Horton W.A., Macchiarelli R. & Mussi M. 1987. Dwarfism in an adolescent from the Italian late Upper Palaeolithic. *Nature*, 330: 60-62.
- Giostra C. 2014. La necropoli di Povegliano Veronese, loc. Ortaia. In E. Possenti (ed): *Necropoli Longobarde in Italia, Indirizzi della ricerca e nuovi dati*. Atti del convegno internazionale (Trento, 26-28 settembre 2011), pp. 239-273, Trento.
- Gracia A., Arsuaga J.L., Martínez I., Lorenzo C., Carretero J.M., de Castro J.M.B. & Carbonell E. 2009. Craniosynostosis in the Middle Pleistocene human cranium 14 from the Sima de los Huesos, Atapuerca, Spain. *Proc. Natl. Acad. Sci. USA*, 106: 6573-6578.
- Hillson S. 2005. *Teeth*. Cambridge University Press, Cambridge.
- Hudson P. 1996. Povegliano. Madonna dell’Uva Secca. Ortaia. La necropoli celtica, romana e longobarda. Scavi 1992-1993. In E. Filippi (ed): *Povegliano Veronese. Scritti sull’ambiente fisico, sulla preistoria, sulla storia romana e longobarda*, pp. 41-60, Povegliano.
- Larsen C.S. 1997. *Bioarchaeology: Interpreting Behavior from the Human Skeleton*. Cambridge Studies in Biological Anthropology. Cambridge University Press, Cambridge.
- Li X., Wagner M., Wu X., Tarasov P., Zhang Y., Schmidt A., Goslar T. & Gresky J. 2013. Archaeological and palaeopathological study on the third/second century BC grave from Turfan, China: Individual health history and regional implications. *Quat. Int.*, 290: 335-343.
- Lovejoy C.O. 1985. Dental wear in the Libben population: its functional pattern and role in the determination of adult skeletal age at death. *Am. J. Phys. Anthropol.*, 68: 47-56.
- Lovejoy C.O., Meindl R.S., Pryzbeck T.R. & Mensforth R.P. 1985. Chronological metamorphosis of the auricular surface of the ilium: a new method for the determination of adult skeletal age at death. *Am. J. Phys. Anthropol.*, 68: 15-28.
- Mays S.A. 1996. Healed limb amputations in human osteoarchaeology and their causes: a case

- study from Ipswich, UK. *Int. J. Osteoarchaeol.*, 6: 101-113.
- Metzler I. 2013. *A Social History of Disability in the Middle Ages: Cultural Considerations of Physical Impairment*. Routledge, New York.
- Micarelli I. 2015. *La Necropoli Longobarda di Povegliano Veronese (VR, VI-VIII sec.): prime indagini antropologiche e contestualizzazione archeologica*. Sapienza, University of Rome.
- Minaire P. 1989. Immobilization osteoporosis: a review. *Clin. Rheumatol.*, 8: 95-103.
- Minozzi S., Catalano P., Pantano W., Caldarini C., Fornaciari G. 2014. Bone Deformities and Skeletal Malformations in the Roman Imperial Age. *Med. Secoli*, 26: 9-22.
- Nemes C.N. 2002. The medical and surgical treatment of the pilgrims of the Jacobean Roads in medieval times: Part 1. The caminos and the role of St. Anthony's order in curing ergotism. *Int. Con. Ser.*, 1242: 31-42.
- Paine R.R., Mancinelli D., Ruggieri M. & Coppa A. 2007. Cranial trauma in Iron Age Samnite agriculturists, Alfedena, Italy: implications for biocultural and economic stress. *Am. J. Phys. Anthropol.*, 132: 48-58.
- Paroli L. 2007. Mondo funerario, in I Longobardi. Dalla caduta dell'impero all'alba dell'Italia, catalogo della mostra. In Chavarria Arnau A. & Brogiolo G.P. (ed): *I Longobardi. Dalla caduta dell'Impero all'alba dell'Italia*. Silvana Editoriale, Milano.
- Phenice T.W. 1969. A newly developed visual method of sexing the os pubis. *Am. J. Phys. Anthropol.*, 30: 297-301.
- Profico A. & Veneziano A. 2015. *Arothron: R Functions for Geometric Morphometrics Analyses*. <http://doi.org/10.5281/zenodo.28194>, <https://github.com/Arothron>.
- R Core Team. 2000. *R language definition. Version 3.4.1. (2017-06-30)*. R foundation for statistical computing, Vienna.
- Rotili M. 2010. I Longobardi: migrazioni, etnogenesi, insediamento. In G. Roma (ed): *I Longobardi del Sud*, pp. 1-77. Giorgio Bretschneider Editore, Roma.
- Sievänen H. 2010. Immobilization and bone structure in humans. *Arch. Biochem. Biophys.*, 503: 146-152.
- Solecki R.S. 1975. Shanidar IV, a Neanderthal flower burial in northern Iraq. *Science*, 190: 880-881.
- Stuckert C.M. & Kricun M.E. 2011. A case of bilateral forefoot amputation from the Romano-British cemetery of Lankhills, Winchester, UK. *Int. J. Paleopathol.*, 1: 111-116.
- Tilley L. & Oxenham M.F. 2011. Survival against the odds: Modeling the social implications of care provision to seriously disabled individuals. *Int. J. Paleopathol.*, 1: 35-42.
- Verano J.W., Anderson L.S. & Franco R. 2000. Foot amputation by the Moche of ancient Peru: Osteological evidence and archaeological context. *Int. J. Osteoarchaeol.*, 10: 177-188.
- Walker P.L. 2001. A bioarchaeological perspective on the history of violence. *Annu. Rev. Anthropol.*, 30: 573-596.
- WHO W.H.O. 2017. Health Topics: Disabilities. <http://www.who.int/topics/disabilities/en/>. Accessed 24/10/2017.
- Więckowski W. 2016. A Case of Foot Amputation from the Wari Imperial Tomb at Castillo de Huarmey, Peru. *Int. J. Osteoarchaeol.*, 26: 1058-1066.

Editor, Giovanni Destro Bisol



This work is distributed under the terms of a Creative Commons Attribution-NonCommercial 4.0 Unported License <http://creativecommons.org/licenses/by-nc/4.0/>